

Original Article

To Determine the Efficacy of a Single Dose of Diclofenac Transdermal Patch as a Post-operative Analgesic After Single-Visit Root Canal Treatment

Amreen Manes¹, Vanshish Sankhyan¹, Sameer Makkar¹, Shabnam Negi¹, Simran Gupta¹

¹Department of Conservative Dentistry and Endodontics, Bhojia Dental College and Hospital, Bhud Baddi HP, Baddi, Solan, Himachal Pradesh, India



***Corresponding author:**
Dr. Vanshish Sankhyan, MDS,
Department of Conservative
Dentistry and Endodontics,
Bhojia Dental College and
Hospital, Bhud Baddi, Baddi,
Himachal Pradesh, India.

vanshishsankhyan96@gmail.
com

Received: 05 August 2024

Accepted: 05 November 2024

Epub Ahead of Print:
09 January 2025

Published: ***

DOI
10.25259/DJIGIMS_22_2024

Quick Response Code



ABSTRACT

Objectives: Efficacy of Diclofenac Transdermal Patch as a post-operative analgesic after single-visit root canal treatment.

Material and Methods: Four hundred patients with symptomatic irreversible pulpitis were divided into two groups. The control group (Group I: 200 patients) was not given any medication, whereas the test group patients (Group II- 200 patients) were administered a transdermal diclofenac patch on the arm. The VAS scale was used to evaluate postoperative pain in both groups at baseline, 4, 8, 24 and 48 hours after treatment. The scores were taken by making a telephone call to the patient or calling the patient back to the department after 48 hours.

Results: The pain intensity decreased in patients who received a transdermal patch, whereas in patients who did not receive it, it did not decrease from baseline to 48 hours.

Conclusion: The patient's post-endodontic pain was effectively relieved for up to 48 hours by the Diclofenac transdermal patch, which was simple to use and had a painless application process.

Keywords: Diclofenac, Pain after root canal treatment, Single-visit RCT, Transdermal Patch

INTRODUCTION

Endodontic post-treatment pain is the most notable problem faced by dental clinicians. The most likely sources of inter-appointment pain in endodontic treatment are associated with endodontic instrumentation, irritating irrigants, temporary restorations with high occlusion, intracanal medicaments and periapical contamination. Therefore, proper operative techniques are necessary for endodontic therapy to be successful, but so is the avoidance and control of post-operative pain.

The most widely used non-steroidal anti-inflammatory drug is diclofenac owing to its analgesic, anti-inflammatory and antipyretic properties. Diclofenac, when given orally, experiences a significant first-pass metabolism, with its bioavailability ranging from 54 to 90%. Currently, various manufacturers are marketing transdermal diclofenac patches, but little is known about their role in post-operative endodontic pain. Transdermal patches can be the choice of the analgesic modality of the near future with its equivalent or, at times, better efficacy over oral doses and better patient acceptance.

This is an open-access article distributed under the terms of the Creative Commons Attribution-Non Commercial-Share Alike 4.0 License, which allows others to remix, transform, and build upon the work non-commercially, as long as the author is credited and the new creations are licensed under the identical terms.

©2024 Published by Scientific Scholar on behalf of Dental Journal of Indira Gandhi Institute of Medical Sciences

Hence, this in-vivo study was designed to investigate the efficacy of transdermal diclofenac patch (Nupatch® 200mg-Zydus Cadila).

MATERIAL AND METHODS

Patient selection criteria

Definite guidelines were set for the patients. Only those who met the requirements were included.

Inclusion criteria

The age group of 16–65 years, good periodontal health, and teeth indicated for single-visit root canal treatment were included.

Exclusion criteria

Patients allergic to NSAIDs, those with a history of systemic diseases, pregnant or lactating mothers and teeth contraindicated for single-visit RCT.

RESULTS

The mean values calculated for each group are given in Table 1. Intergroup comparison is shown in Table 2.

There was a decrease in pain intensity in patients in whom a transdermal patch was given, whereas, in patients in whom the patch was not given, there was no decrease in pain intensity from baseline to 48 hours. Also, there was no complaint of any side effects in the group in which the patch was given.

Time period	Control group	Test group
Baseline	202.16	198.84
4 hours	246.88	154.12
8 hours	266.77	200.15
24 hours	275.53	125.47
48 hours	271.81	129.19

	Baseline	4 hours	8 hours	24 hours	48 hours
Mann Whitney U Value test	19669	10725	6746	4993.5	5738
P value	0.77	<0.05	<0.05	<0.05	<0.05
Z ratio	0.29	8.02	11.46	12.98	12.33

DISCUSSION

Dental therapy is often associated with pain, and patients who have experienced inadequately managed pain during dental care may avoid or postpone receiving treatment, which might make it difficult to treat them.^[1] The effective management of post-operative pain is helpful as it increases patient comfort and satisfaction and improves overall treatment outcomes.

NSAIDs are most commonly used and prescribed to relieve post-operative dental pain.^[2] Although NSAIDs are generally safe, they are usually prescribed in low doses and for short periods due to the potential for gastrointestinal side effects that can increase with higher doses. Because NSAIDs can penetrate tissues well and maintain high concentrations at sites of inflammation, they are often very effective for treatment. To address the limitations of oral NSAIDs, topical or transdermal drug delivery systems have been developed.^[3] Diclofenac patch was the first NSAID approved for the transdermal delivery method.^[4] Since several patients had discomfort within the first 24 hours of beginning root canal therapy, a 48-hour assessment period was selected for this study.^[5]

Transdermal patches are effective in both acute and chronic pain management with a lower incidence of side effects.^[6] It is preferably applied for 24 hours to produce rapid pain relief. The plasma levels of the patch (20–50 ng/mL) are lower compared to the oral route, but they are sustained for a longer duration.^[7] They function on crystal reservoir technology hence, continuous controlled drug delivery is ensured into the circulation.^[8] From the stratum corneum, the drug penetrates the epidermis, from there to the dermis through the network of local capillaries and finally to systemic circulation.^[4]

The efficacy of transdermal patch was evaluated by dividing the patients into two groups [Figure 1]:

Group 1 - Control Group: It comprised 200 patients with tooth pain, selected based on inclusion and exclusion criteria. Single-visit root canal treatment was performed. The transdermal patch was not given to the patients in this group.

Group 2 - Test Group: It comprised 200 patients with tooth pain and was finalized after evaluating the inclusion and exclusion criteria. Single-visit root canal treatment was done. After completion of the treatment, NuPatch was given to the patients in this group. The patch was applied by the clinician on the arm of the patient for a period of 48 hours.

Pain intensity was evaluated from the patients of both groups using VAS at baseline, 4, 8, 24 and 48 hours by making a telephone call to the patient or calling the patient to the department after 48 hours. In numerous previous studies, VAS has been used to assess pain following endodontic therapy. Although the VAS failure rate is typically between

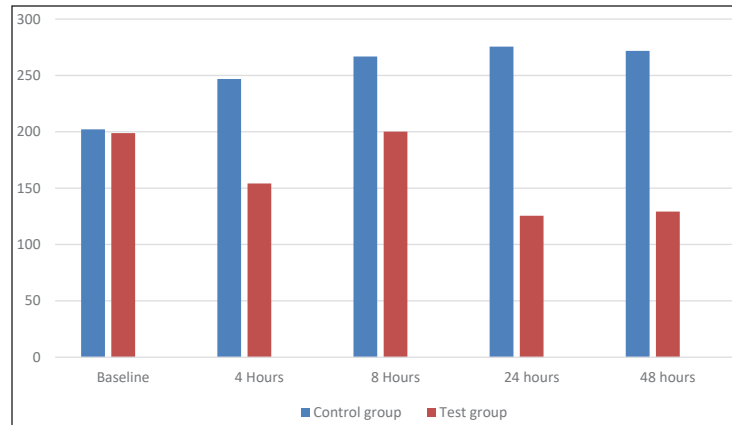


Figure 1: Mean values of control and test group.

4 and 11%, this can be prevented if the patient is properly informed.^[9] Mann–Whitney test was performed to compare both groups, revealing statistically significant differences.

Galer *et al.*^[10] concluded that the diclofenac patch was safe and effective in controlling pain after sports injury and had no systemic effect. In a research conducted by Predel *et al.*,^[11] diclofenac was administered in patch form for soft tissue injuries, and it was concluded that the patches were effective in treating blunt trauma. Funk *et al.*^[12] concluded that transdermal patches provided better pain relief in the early postoperative period after arthroscopic shoulder surgery as compared to oral diclofenac tablets. In a study performed by Bhaskar *et al.*,^[13] both an oral 150 mg diclofenac tablet and a transdermal diclofenac patch of 100 mg showed similar analgesic efficacy when used for post-dental extraction analgesia in orthodontic patients. It was also concluded that there was a 65% reduction in pain during the immediate 2 post-operative days in patients for whom transdermal patches were prescribed.

In the present study, there was no complaint of any gastric discomfort by the patients, as was also concluded by Mangal *et al.*^[2] Mason *et al.*^[14] in their study emphasized the safety profile of diclofenac patches and did not show any increased chances of renal failure or any serious gastrointestinal complications. However, in the study done by Tejaswi *et al.*,^[4] 3 out of 20; in the study by Dhanapal *et al.*,^[15] 4 out of 50; and in the study by Krishnan R *et al.*,^[16] 3 out of 30 patients complained of gastric discomfort.

A study conducted by Rajeswari *et al.*^[17] showed that there was no statistical difference at any time interval in post-operative pain management between two routes of diclofenac following dental implant placement. Another important concern, as noticed by Hitesh B *et al.*^[18] related to transdermal drug delivery methods, is that they take longer time of duration for onset and offset as compared to other drug delivery methods to control pain.

CONCLUSION

The Diclofenac patch is user-friendly, and its painless application process makes it an incredibly convenient option for patients undergoing endodontic procedures. Transdermal patches have advantages, but they cannot be used for acute pains due to slow onset and may cause skin irritation in some patients.

The true potential of transdermal diclofenac patches in various dental situations can only be clearly defined after conducting extensive clinical trials with a large sample size to demonstrate their effectiveness and safety. Further research is required to assess the use of transdermal pain relievers in other areas of dentistry and explore this method of delivery.

Ethical approval

The research/study was approved by the Institutional Review Board, approval number BDC/BUDH/SF/787 dated 22.10.2028.

Declaration of patient consent

The authors certify that they have obtained all appropriate patient consent.

Financial support and sponsorship

Nil

Conflicts of interest

There are no conflicts of interest.

Use of artificial intelligence (AI)-assisted technology for manuscript preparation

The authors confirm that there was no use of artificial intelligence (AI)-assisted technology for assisting in the

writing or editing of the manuscript, and no images were manipulated using AI.

REFERENCES

- Bachalli PS, Nandakumar H, Srinath N. A comparative study of diclofenac transdermal patch against oral diclofenac for pain control following removal of mandibular impacted third molars. *J Maxillofac Oral Surg* 2009;8:167-72.
- Mangal S, Mathew S, Murthy BVS, Hegde S, Dinesh K, Ramesh P. The efficacy of transdermal and oral diclofenac for post-endodontic pain control: A randomised controlled trial. *Indian J Dent Res* 2020;31:53-56.
- Lionberger DR, Brennan MJ. Topical nonsteroidal anti-inflammatory drugs for the treatment of pain due to soft tissue injury: Diclofenac epolamine topical patch. *J Pain Res* 2010;3:223-33.
- Tejaswi DV, Prabhuj ML, Khaleelahmed S. Comparative evaluation of transdermal diclofenac patch with oral diclofenac as an analgesic modality following root coverage procedures. *Gen Dent* 2014;62:68-71.
- Cordero JA, Alarcon L, Escribano E, Obach R, Domenech J. A comparative study of the transdermal penetration of a series of nonsteroidal antiinflammatory drugs. *J Pharm Sci* 1997;86:503-8.
- Agarwal A, Gautam S, Gupta D, Singh U. Transdermal diclofenac patch vs eutectic mixture of local anesthetics for venous cannulation pain. *Can J Anaesth* 2007;54:196-200.
- Diwan V, Srinivasa TS, Ramreddy KY, Agrawal V, Nagdeve S, Parvez H. A comparative evaluation of transdermal diclofenac patch with oral diclofenac sodium as an analgesic drug following periodontal flap surgery: A randomized controlled clinical study. *Indian J Dent Res* 2019;30:57-60.
- Bhowmik D, Bhattacharjee C, Chandira, MC, Jayakar, B, Sampath, KP. Recent advances in transdermal drug delivery system. *Int J Pharm Tech Res* 2010;2:68-77.
- Williamson A, Hoggart B. Pain: A review of three commonly used pain rating scales. *J Clin Nurs* 2005;14:798-804.
- Galer BS, Rowbotham M, Perander J, Devers A, Friedman E. Topical diclofenac patch relieves minor sports injury pain: Results of a multicenter controlled clinical trial. *J Pain Symptom Manage* 2000;19:287-94.
- Predel HG, Koll R, Pabst H, Dieter R, Gallacchi G, Giannetti B, *et al.* Diclofenac patch for topical treatment of acute impact injuries: A randomised, double blind, placebo controlled, multicentre study. *Br J Sports Med* 2004;38:318-23.
- Funk L, Umaar R, Molajo A. Diclofenac patches for postoperative shoulder pain. *Int J Shoulder Surg* 2008;2:47-8.
- Bhaskar H, Kapoor P, Ragini None. Comparison of transdermal diclofenac patch with oral diclofenac as an analgesic modality following multiple premolar extractions in orthodontic patients: A cross over efficacy trial. *Contemp Clin Dent* 2010;1:158-63.
- Mason L, Moore RA, Edwards JE, Derry S, McQuay HJ. Topical NSAIDs for acute pain: A meta-analysis. *BMC Fam Pract* 2004;5:10.
- Dhanapal S, Sureshababu NM. Efficacy of single dose of transdermal patch as a pre-operative analgesic in root canal treatment-a randomized clinical trial. *J Pharm Sci & Res* 2016;8:125.
- Krishnan S, Sharma P, Sharma R, Kumar S, Verma M, Chaudhary Z. Transdermal diclofenac patches for control of post-extraction pain. Pilot randomized controlled double-blind study. *Oral Maxillofac Surg.* 2015 Mar;19(1):5-12. doi: 10.1007/s10006-013-0422-5. Epub 2013 Jul 14. PMID: 23852077.
- Raja Rajeswari S, Gowda T, Kumar T, Mehta DS, Arya K. Analgesic efficacy and safety of transdermal and oral diclofenac in postoperative pain management following dental implant placement. *Gen Dent* 2017;65:69-74.
- Bari H. A prolonged release parenteral drug delivery system-an overview. *Int J Pharm Sci Rev Res* 2010;3:1.

How to cite this article: Manes Amreen, Sankhyan Vanshish, Makkar Sameer, Negi Shabnam, Gupta Simran, To Determine the Efficacy of a Single Dose of Diclofenac Transdermal Patch as a Post-operative Analgesic After Single-Visit Root Canal Treatment. *Dent J Indira Gandhi Int Med Sci.* doi: 10.25259/DJIGIMS_22_2024