

Case Report

A Case Study of Castleman's Disease: Exploration of Literature and Insights

Supriya H¹, Jayadeep NA², Shaila Mulki¹, Anitha Dayakar¹

¹Department of Oral Pathology & Microbiology, KVG Dental College & Hospital, Sullia, ²Department of Oral & Maxillofacial Surgery, Government Hospital, Puttur, India



*Corresponding author:

Dr. Supriya H, MDS,
Department of Oral Pathology
& Microbiology, KVG Dental
College & Hospital, Sullia,
Kurunji Bagh, Sullia, Dakshina
Kannada, India.

supriyakarunakar@gmail.com

Received: 03 October 2024

Accepted: 22 November 2024

Epub Ahead of Print:
19 December 2024

Published: ***

DOI

10.25259/DJIGIMS_31_2024

Quick Response Code



ABSTRACT

The rarity and spectra of clinical and pathological presentations of the disease have made Castleman's disease an enigma. Mimics of Castleman disease are associated with symptoms that are life-threatening and cannot be disregarded, making histopathological diagnosis imperative. The diagnosis is based on excluding other infectious, autoimmune, or lymphoproliferative mimics. Here, we present an aberrant case of idiopathic mass in an unusual location diagnosed as Castleman's disease histopathologically and reinforced immunohistochemically.

Keywords: Castleman's disease, Hyaline vascular variant, Unicentric

INTRODUCTION

Castleman's disease (CD) is a rarely encountered, heterogeneous lymphoproliferative disorder. Clinically, unicentric Castleman's disease (UCD), confined to a specific anatomical location, and multicentric Castleman's disease (MCD), with systemic inflammatory symptoms and organ dysfunction, are described. Histologically, variants include the hyaline-vascular (HV) type (91%), the plasma cell (PC) type, and the mixed type.^[1] Here, we report a case of idiopathic UCD of the hyaline vascular type, followed by a literature review.

CASE REPORT

A 65-year-old female patient reported a complaint of a mass in the left submandibular area for four months. The lesion was mostly asymptomatic, except for occasional discomfort.

On extraoral examination, a non-tender, firm mass of size 3 × 4 cm was palpated in the left submandibular area with no evidence of lymphadenopathy or organomegaly [Figure 1]. There was no compression of the surrounding structures upon examination of the overlying skin. Intra-oral examination showed multiple missing teeth and no signs of infection, inflammation, or other oral pathologies. Examination of the ear, nose, nasopharynx, and oropharynx showed no abnormality. Fine needle aspiration attempts were non-contributive. Hematological reports were within normal limits, with slight anemia. Serological tests for human immunodeficiency virus (HIV) were reported negative. Further, radiographs showed no abnormalities. Ultrasonography revealed a hypoechoic mass in the left submandibular region with no proof of calcification or necrosis. The lesion was described as vascular, 3 × 3 cm mass, possibly lymphoid with normal submandibular glands.

This is an open-access article distributed under the terms of the Creative Commons Attribution-Non Commercial-Share Alike 4.0 License, which allows others to remix, transform, and build upon the work non-commercially, as long as the author is credited and the new creations are licensed under the identical terms.

©2024 Published by Scientific Scholar on behalf of Dental Journal of Indira Gandhi Institute of Medical Sciences

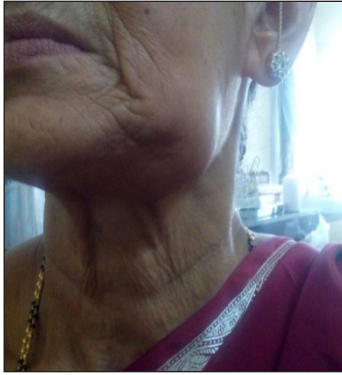

Figure 1: Photograph showing swelling on the left side of the neck.

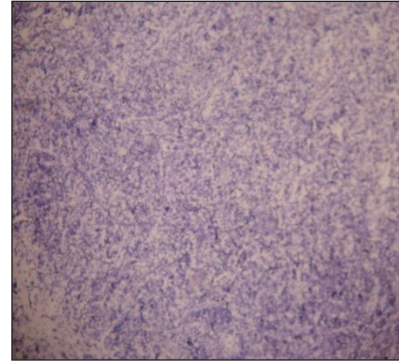


Figure 3: Immunohistochemical expression of B cell lymphoma-2 showing negativity. (BCL-2 stain, 40x).

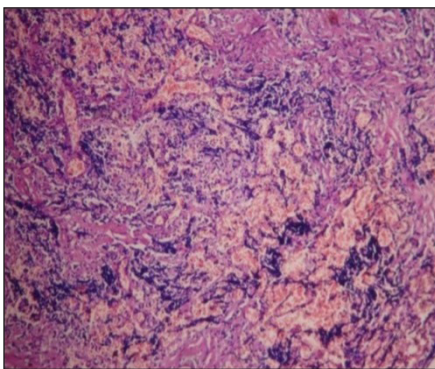


Figure 2: Characteristic onion skin appearance on histopathology [hematoxylin & eosin (H&E) stain].

Surgical resection of the swelling was recommended. Surgical excision was carried out in its entirety under general anesthesia, and the patient remained asymptomatic postoperatively.

The histopathological report showed lymphoid tissue with areas of the germinal center consisting of lymphocytes and macrophages. Areas of lymphoid aggregates were separated by collagenous septa. Interfollicular areas showed abundant vascular proliferation. Few vessels also showed hyalinised walls and proliferating endothelial cells encircled by concentric layers of lymphocytes, creating an 'onion skin' pattern [Figure 2].

Identification of B-cell lymphoma-2 (BCL-2) expression in the follicle center cells immunohistochemically is a key marker used in distinguishing follicular lymphoma from benign follicular hyperplasia. Immunohistochemical expression of BCL-2 on the lesion showed negativity [Figure 3], and the lymphoma diagnosis was excluded. Correlating with clinical and histopathologic findings and supported by immunohistochemistry findings, a diagnosis of UCD (hyaline vascular type) was given. No recurrence or new sites

of lymphadenopathy were observed for 12 months following the surgery.

DISCUSSION

Benjamin Castleman, in 1956, identified a condition resembling thymomas that is now referred to as Castleman disease (CD).^[2] This condition is marked by hyperplasia of lymphoid follicles and hyalinised vessels extending into the germinal centers.^[3] It has been synonymously referred to as angiofollicular lymph node hyperplasia, angiomatous lymphoid hamartoma, follicular lympho-reticuloma, large lymph node hyperplasia, and lymph nodal hamartoma.^[4] According to the Castleman Disease Collaborative Network (CDCN), it is now described as a collection of uncommon conditions characterized by swollen lymph nodes, a wide range of inflammatory symptoms, and abnormal test results, and further classified into four subtypes:

1. Unicentric Castleman disease (UCD)
2. Polyneuropathy, organomegaly, endocrinopathy, monoclonal plasma cell disorder, and skin changes (POEMS)-associated multicentric Castleman disease (POEMS-MCD)
3. Human herpesvirus 8 (HHV-8)-associated multicentric Castleman disease (HHV-8 + MCD)
4. HHV-8-negative/idiopathic multicentric Castleman disease (IMCD)^[5]

UCD subtype is typically associated with a more subtle clinical presentation, where the majority of patients remain asymptomatic. Complete remission is achieved with surgical resection of the involved lymph node, and recurrence is rare, as substantiated by case reports.^[6]

The MCD subtype associated with POEMS is termed POEMS syndrome.^[7] Further, the combination of symptoms, including thrombocytopenia, anasarca, myelofibrosis, renal failure, and organomegaly (TAFRO), is termed TAFRO syndrome.^[3]

HHV-8 positive MCD (HHV-8 + MCD) is associated with HHV-8 infection and occurs in patients with underlying immunodeficiency leading to MCD.^[8] The last clinical subtype is IMCD, which is extremely sporadic.^[6] Transformation of multicentric form into malignancies like Kaposi sarcoma, BCL-2, Hodgkin's lymphoma, and plasmacytoma is not rare.^[9]

Incidence of CD can occur at any age, primarily in adults (60% female),^[5] and the UCD variant can also appear in children.^[6] Literature review suggests its occurrence anywhere in the body along the lymphatic chain.^[10] It is mostly found in the chest (70%) and other sites, including the neck and abdomen. Extralymphatic involvement may include the lungs, larynx, parotid glands, pancreas, meninges, and muscles.^[11]

Literature suggests that the pathogenesis of CD is likely a clonal neoplastic process of follicular dendritic cells with the absence of association with any viral infections. Interleukin-6 (IL-6) functions as a promoter for plasma cell proliferation and the production of immunoglobulins.^[12] Genetic sequencing has revealed somatic and germline mutations, including vascular endothelial growth factor (VEGF), IL-1, IL-2, C-X-C Motif Chemokine 13 (CXCL13), and tumor necrosis factor (TNF), pertinent to the pathophysiology of IMCD.^[13]

Clinically, signs of UCD are either incidental or sporadic systemic manifestations. On the contrary, MCD presents frequent constitutional symptoms, autoimmune manifestations, peripheral neuropathy, or syndrome-related features.^[12]

The absence of significant clinical symptoms in UCD makes diagnostic modalities a wide spectrum of choices. On radiodiagnosis, most of the case reports evidenced non-invasive masses with well-defined borders. Computed tomography (CT) can be utilized to exclude fatty or cystic masses. CD classically presented slightly hypodense to isodense lesions on enhanced CT images.^[14] Contrast CT helps to rule out thymoma and lymphoma, as these tumors do not enhance compared to significant contrast enhancement associated with lesions that arise from vessels.^[15]

The ultrasound picture resembles lymphoma.^[16] Angiography and magnetic resonance imaging (MRI) may also aid in diagnosis. MRI findings showed lesions as regular and well circumscribed.^[14] Scintigraphy, though not able to differentiate CD from malignant tumors, is important in both the diagnosis and management, in particular, to rule out multifocal disease, identify the locations of involvement, and monitor the progression of the illness as well as its response to treatment.^[17] Further review of case reports suggests that imaging study is of limited value in the diagnosis of CD.^[10]

Histopathological examination is a confirmative aid in the diagnosis of CD. Careful evaluation and comparison of histology of other lymphoproliferative diseases are necessary. The most prevalent variety in histopathology is the HV type. (90% of cases).^[18] Small lymphoreticular follicles dispersed across hypervascular hyalinised stroma are the hallmarks of the HV variation.^[19] The follicles are round and variable in size, surrounded by a cuff of small lymphocytes arranged in concentric 'onion skin' layers, with germinal centers frequently demonstrating atrophy with radically penetrating blood vessels.^[20] PC variant is rare but more aggressive, characterized by mature plasma cell clusters between lymph follicles.^[18] Russell bodies and larger lymphoreticular nodules with less hyalinised blood arteries are characteristics of the plasma cell type, which differs from the HV type.^[10] MCD may present mixed histology with intact preservation of lymph node architecture, dilated sinuses, and paracortical hyperplasia with prominent vascular proliferation. Most of the MCD cases present with a plasma cell variant.^[12]

Studies reveal that CD lacks immunophenotypic traits and does not have any particular immunological markers: immunohistochemical labeling positivity for CD20 in follicles and CD3 in the interfollicular region. Within the germinal center, BCL2 is negative. CD21, CD35, and CD23 display the follicular dendritic meshworks.^[21] BCL2 and Cyclin D1 staining patterns can be used to exclude mantle cell lymphoma.^[22] Thus, diagnosis is based on combined clinical and peculiar histopathological features.

The CDCN's recent guidelines served as the basis for the development of additional classification and diagnostic criteria.^[5] The following criteria were used for classification: (i) excluding conditions that may exhibit Castleman-like histology on lymph node biopsy.^[23] The following pathologies should be ruled out: autoimmune diseases (juvenile idiopathic arthritis, autoimmune lymphoproliferative syndrome, rheumatoid arthritis, systemic lupus erythematosus, Still disease), malignant/lymphoproliferative disorders (Hodgkin lymphoma, non-Hodgkin lymphoma, multiple myeloma, primary lymph node plasmacytoma, follicular dendritic cell sarcoma) and infection-related disorders (Epstein-Barr virus-related mononucleosis or chronic viral infection, inflammation and lymphadenopathy caused by cytomegalovirus, toxoplasmosis, active tuberculosis);^[24] (ii) testing for HHV-8 utilizing particular immunohistochemistry; (iii) staging the disease: unicentric (one lymph node station) versus multicentric (disseminated disease); and (iv) context of HIV infection

Careful evaluation of the disease, location, clinical symptoms, and biochemical and immunological indicators determines the best course of treatment for CD.^[20] Resection of the mass

is the treatment of choice in cases of UCD. When a complete resection is unattainable in UCD, partial resection with radiation therapy (doses ranging from 27 to 45 Gy) can be attempted.^[25,26]

MCD cases may require antiretroviral therapy. Corticosteroids, rituximab, and chemotherapy drugs from the combination chemotherapy regimen have been shown to be beneficial in idiopathic MCD patients.^[24] Recurrence is rarely evidenced. A novel and promising immunotherapeutic strategy involves identifying and eliminating CD20-positive B cells, which are the source of the dysregulated production of human IL-6, VEGF, and other cytokines.^[27]

CONCLUSION

The CD is a complex disorder with distinct features. It includes a broad array of pathologic findings, manifestations, and associations. Isolated Castleman's disease in the submandibular region is very uncommon. Histopathological evaluation followed by a panel of appropriate immunohistochemical markers (to rule out malignancies like lymphoma) is the only way to make an accurate diagnosis. Although rare, the CD should be kept in mind as a possible differential diagnosis for any submandibular or neck masses.

Ethical approval

Institutional Review Board approval is not required.

Declaration of patient consent

The authors certify that they have obtained all appropriate patient consent.

Financial support and sponsorship

Nil.

Conflicts of interest

There are no conflicts of interest.

Use of artificial intelligence (AI)-assisted technology for manuscript preparation

The authors confirm that there was no use of AI-assisted technology for assisting in the writing or editing of the manuscript and no images were manipulated using AI.

REFERENCES

- Martino G, Cariati S, Tintisona O, Veneroso S, De Villa F, Vergine M, et al. Atypical lymphoproliferative disorders: Castleman's disease. Case report and review of the literature. *Tumori* 2004;90:352-5.
- Yu L, Tu M, Cortes J, Xu-Monette ZY, Miranda RN, Zhang J, et al. Clinical and pathological characteristics of HIV- and HHV-8-negative Castleman disease. *Blood* 2017;129:1658-68.
- Masaki Y, Arita K, Sakai T, Takai K, Aoki S, Kawabata H. Castleman disease and TAFRO syndrome. *Ann Hematol* 2022;101:485-90.
- Shastry S, Gadda A. Castleman's disease: Hyaline vascular type. *Med J DY Patil Univ* 2014;7:73-5. Available from: <https://doi.org/10.4103/0975-2870.122791>
- Available from: <https://cdcn.org/castleman-disease/overview/> [Last accessed on 2024 September 2].
- Butzmann A, Kumar J, Sridhar K, Gollapudi S, Ohgami RS. A review of genetic abnormalities in unicentric and multicentric Castleman disease. *Biology (Basel)* 2021;10:251.
- Yu H, Yao F, Li Y, Li J, Cui QC. Castleman disease variant of POEMS syndrome complicated with multiple cerebral infarction: A rare case report and review of literature. *Int J Clin Exp Pathol* 2015;8:13578-83.
- Leroy S, Moshous D, Cassar O, Reguerre Y, Byun M, Pedergnana V, et al. Multicentric Castleman disease in an HHV8-infected child born to consanguineous parents with systematic review. *Pediatrics* 2012;129:e199-203.
- Eszes N, Tamási L, Csekeő A, Csomor J, Szepesi A, Varga G, et al. Unicentric mixed variant Castleman disease associated with intrabronchial plasmacytoma. *Diagn Pathol* 2014;9:64.
- Jiang L, Zhao LY, Liu Y, Zhao YF. Castleman's disease of the neck: Report of 4 cases with unusual presentations. *J Oral Maxillofac Surg* 2011;69:1094-9.
- Bonekamp D, Horton KM, Hruban RH, Fishman EK. Castleman disease: The great mimic. *Radiographics* 2011;31:1793-807.
- Saeed-Abdul-Rahman I, Al-Amri AM. Castleman disease. *Korean J Hematol* 2012;47:163-77.
- Carbone A, Borok M, Damania B, Gloghini A, Polizzotto MN, Jayanthan RK, et al. Castleman disease. *Nat Rev Dis Primers* 2021;7:84.
- Zhao S, Wan Y, Huang Z, Song B, Yu J. Imaging and clinical features of Castleman disease. *Cancer Imaging* 2019;19:53.
- Quint LE. Imaging of anterior mediastinal masses. *Cancer Imaging* 2007;7 Spec No A:S56-62.
- Pitot MA, Tahboub Amawi AD, Alexander LF, LeGout JD, Walkoff L, Navin PJ, et al. Imaging of Castleman Disease. *Radiographics* 2023;43:e220210.
- Yeh CM, Chou CM, Wong LC. Castleman's disease mimicking intrapulmonary malignancy. *Ann Thorac Surg* 2007;84:e6-7.
- Korbi AE, Jellali S, Jguiri M, Bellalah A, Ferjaoui M, Bouatay R, et al. Castleman's disease of the neck: A case report and literature review. *Pan Afr Med J* 2020;37:369.
- Chen CC, Jiang RS, Chou G, Wang CP. Castleman's disease of the neck. *J Chin Med Assoc* 2007;70:556-8.
- Lin CY, Huang TC. Cervical posterior triangle Castleman's disease in a child - case report & literature review. *Chang Gung Med J* 2011;34:435-38
- Chang Y, Ma Y, Chang C, Li W. Analysis of immunophenotypic features in hyaline vascular type Castleman disease. *Diagn Pathol* 2023;18:132.
- Fetica B, Pop B, Lisencu C, Rancea AC, Coman A, Cucuianu A, et al. Castleman Disease. A report of six cases. *Clujul Med* 2014;87:192-7.

23. Oksenhendler E, Boutboul D, Fajgenbaum D, Mirouse A, Fieschi C, Malphettes M, *et al.* The full spectrum of Castleman disease: 273 patients studied over 20 years. *Br J Haematol* 2018;180:206–16.
24. Wojtyś M, Piekarska A, Kunc M, Ptaszyński K, Biernat W, Zaucha JM, *et al.* Clinicopathological comparison and therapeutic approach to Castleman disease – a case-based review. *J Thorac Dis* 2019;11:4859–74.
25. Palma DA, Dar AR, Millington SJ, Smits CL, Rizkalla K, Inculat R. Castleman's disease in children: Report of 2 cases and clinicopathologic review. *J Pediatr Hematol Oncol* 2004;26:264–6.
26. Massey GV, Kornstein MJ, Wahl D, Huang XL, McCrady CW, Carchman RA. Angiofollicular lymph node hyperplasia (Castleman's disease) in an adolescent female. Clinical and immunologic findings. *Cancer* 1991;68:1365–72.
27. Rao S, Ramesh A, Rajkumar A, Arcot R, Kuruvilla S. Persistent or recurrent Castleman's disease – Look out for a lurking lymphoma!. *Indian J Med Paediatr Oncol* 2011;32:162–4.

How to cite this article: H Supriya, NA Jayadeep, Mulki Shaila, Dayakar Anitha, A Case Study of Castleman's Disease: Exploration of Literature and Insights. *Dent J Indira Gandhi Int Med Sci.* doi: 10.25259/DJIGI MS_31_2024